

Duck-Young Yoon<sup>1</sup>, Young-Gyu Lee<sup>2</sup>, Chung-Sik Do<sup>3</sup>, Uhyeong Cho<sup>4</sup>

1. Pusan Ye Dental Office / 2. Ulsan BS Orthodontics  
3. Smile line Orthodontics / 4. The Goreun Orthodontic Clinic

## Introduction and Background


The priority in treating growing children with anterior crossbite is to determine whether it is because of skeletal or functional problem. We will have to carefully evaluate skeletal class III with shallow bites and abnormal maxilla and mandible growth to determine treatment time. In the case of functional class III with CO-CR discrepancy or deep anterior crossbite is often seen and sometimes becomes skeletal III as it grows, therefore should be treated immediately.

Functional appliances like face-mask have traditionally been used to correct functional Class III. However, these appliances are difficult to wear it well because they are located on the extraoral and often do not get cooperation

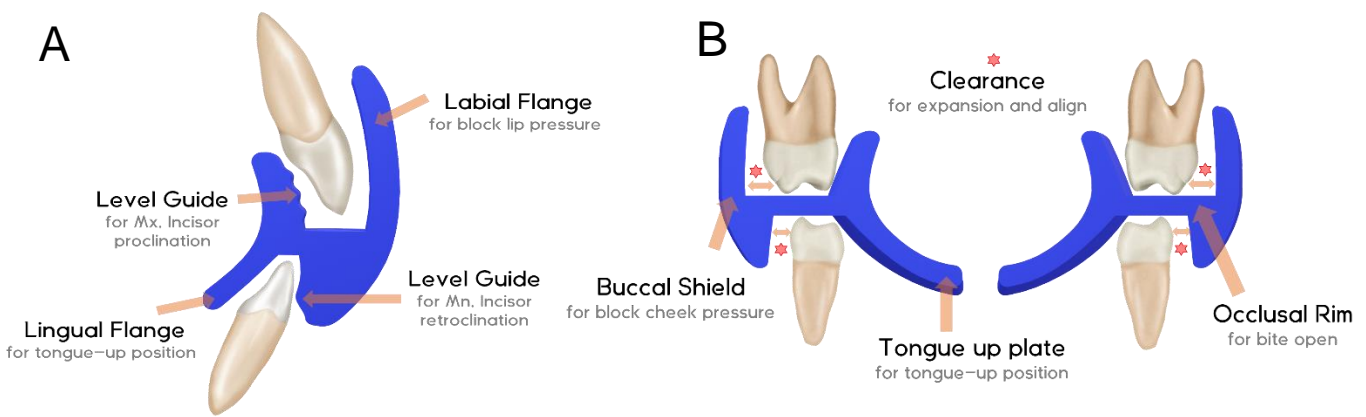
from many growing-up patients due to inconvenience such as wearing them for a minimum wearing time during the day. In order to overcome this discomfort and to obtain good patient cooperation, we would like to introduce new functional appliance, as we have treated functional class III malocclusion.

This device known as PreOrtho® is made of Thermoplastic silicone, which is provided in the form of prefabricated to fit the average dental arch of children. Unlike other appliances, this appliance is able to achieve good treatment results by wearing 6 to 10 hours during evening and sleeping time. Children have to exercise myofunctional training to get good results.

## Appliance



**Fig.1 PreOrtho® Type III, designed for functional Class III case**



**Fig.2 PreOrtho® cross-sectional view, A. Lateral, B. Frontal (molar area)**

This appliance was invented by Dr. Otsuka Atsushi. It is designed according to malocclusion type and dental arch size. Type III is designed for functional class III malocclusion. Its labial flange helps patients breathe with nose by blocking his/her mouth with stimulating maxillary growth. In order to obtain a proper overjet, the maxillary lingual flange and level guide contact with the palatal surface of maxillary incisors for proclination. In case of mandible, teeth level guide is positioned on labial flange

for retroclination. Tongue up plate is used to raise the tongue and press the maxillary teeth and palatal vault, to help the maxilla widening. The labial flange for the maxillary teeth serves as a lip bumper to block the pressure of the upper lip and cheek. Clearance between molar and occlusal rim is space for expansion and alignment. Occlusal rim act as bite plate to remove premature contact of incisors.

### Case summary

We report the couple of functional CI III cases with anterior crossbites using prefabricated functional Appliance (PreOrtho®).

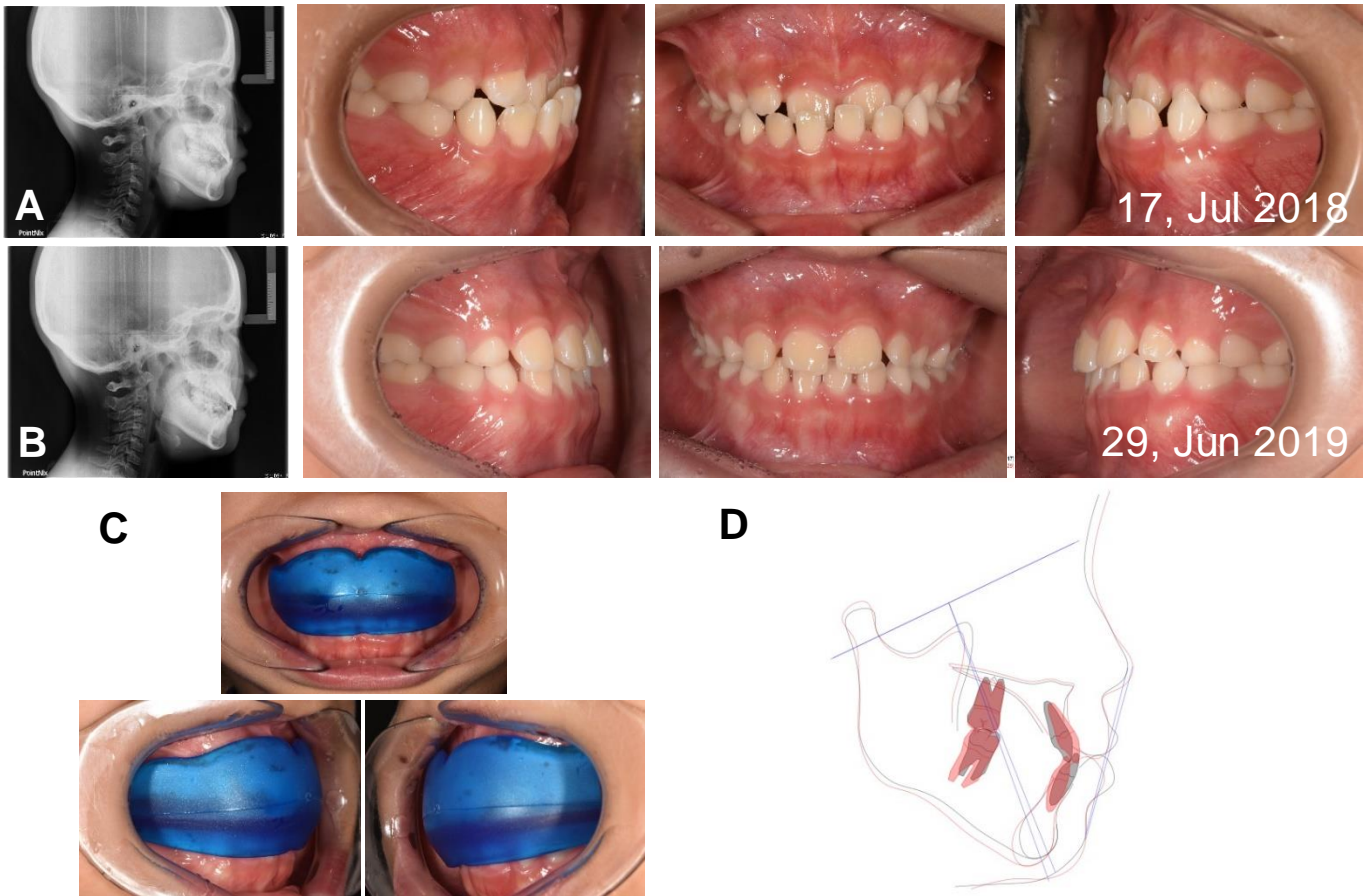
The children ranged in age from 5 to 10 years and were diagnosed as functional class III malocclusion through the diagnostic process. The children were asked to wear PreOrtho® in the evening and during sleep for 6 to 10 hours a day. Initial wearing was performed with chewing with the device in the mouth to adapt to the device and induce rapid movement of the incisors.

After the anterior crossbite was

resolved, the cephalogram was used to compare before and after treatment. After treatment, labial inclination of maxillary anterior teeth was observed, while the mandibular incisors was inclined lingually. Through this movements, the mandible was rotated downward and backward, and the anterior crossbite was corrected.

We thought that effects of this treatment are similar to that of conventional treatments like Frankel and facemask appliance.

## Case #1



**Fig. 3 Treatment result of case #1,  
A. Before treatment, B. After treatment,  
C. PreOrtho<sup>®</sup> in mouth, D. Superimposition of cephalogram**

This Patient was 8 years old boy and had a mixed dentition with anterior crossbite. He showed functional shift during the bite. The PreOrtho<sup>®</sup> appliance was worn for 11 months. He was been trained myofunctional exercise during treatment. His anterior crossbite was improved. When comparing before and after cephalogram superimposition, we can see the labial inclination of maxillary incisors and lingual inclination of mandibular incisors, and anterior crossbite is improved by clockwise rotation of mandible. The high position of tongue is widening the width of the maxilla.

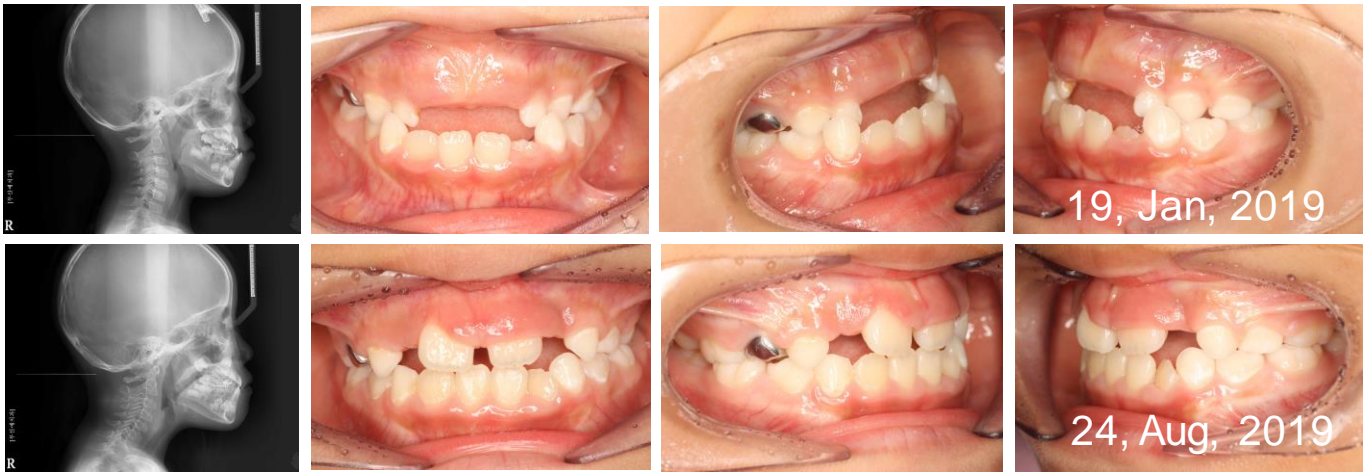The main advantage of this appliance is that the young children can easily adapt to the appliance and cooperate well.

As the anterior crossbite improved, he wore the device himself better and trained himself to close lip tight and swallow well. In early treatment, the crossbite of the central incisors was improved first.

After 11 months, Lateral incisors was erupted completely and the crossbite was disappeared, the treatment was stopped. But we have to observe prognosis of mandibular growth continuously .



## Case #2

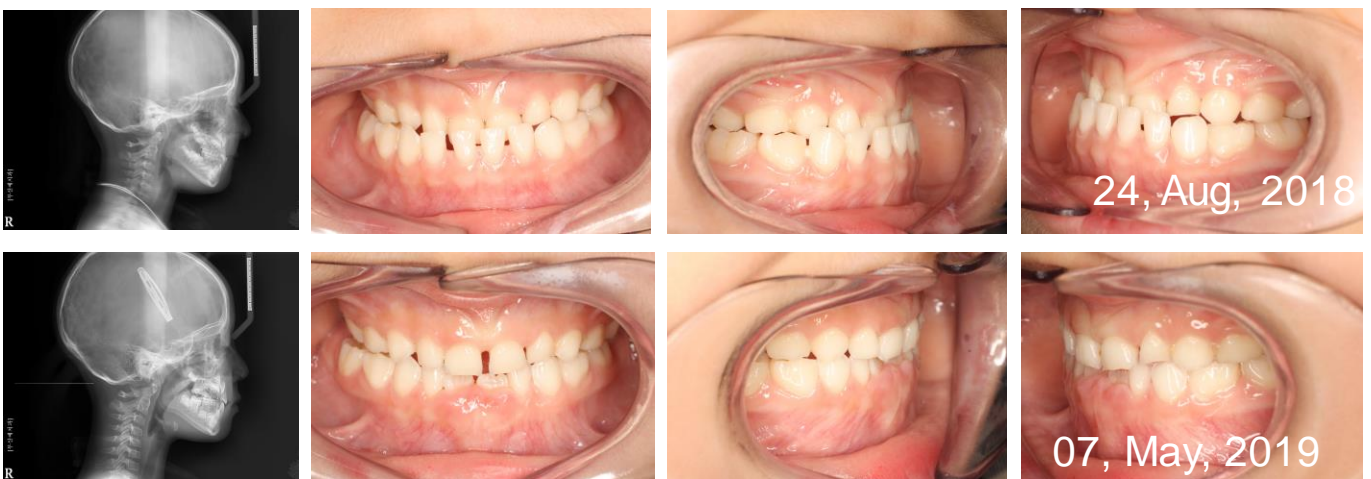

**Fig.4 Treatment result of case #2**

This patient was 6 years old girl and had an early mixed dentition. At the time of deciduous period, she had anterior crossbite. Her mother also had Class III malocclusion. the maxillary canine width was narrower than the mandible.

To induce normal eruption of maxillary incisors, the PreOrtho<sup>®</sup> appliance was worn for 6 months every 8 hours in the night time. She was trained myofunctional therapy in wearing of the appliance.

## Case #3



**Fig.5 Treatment result of case #3**

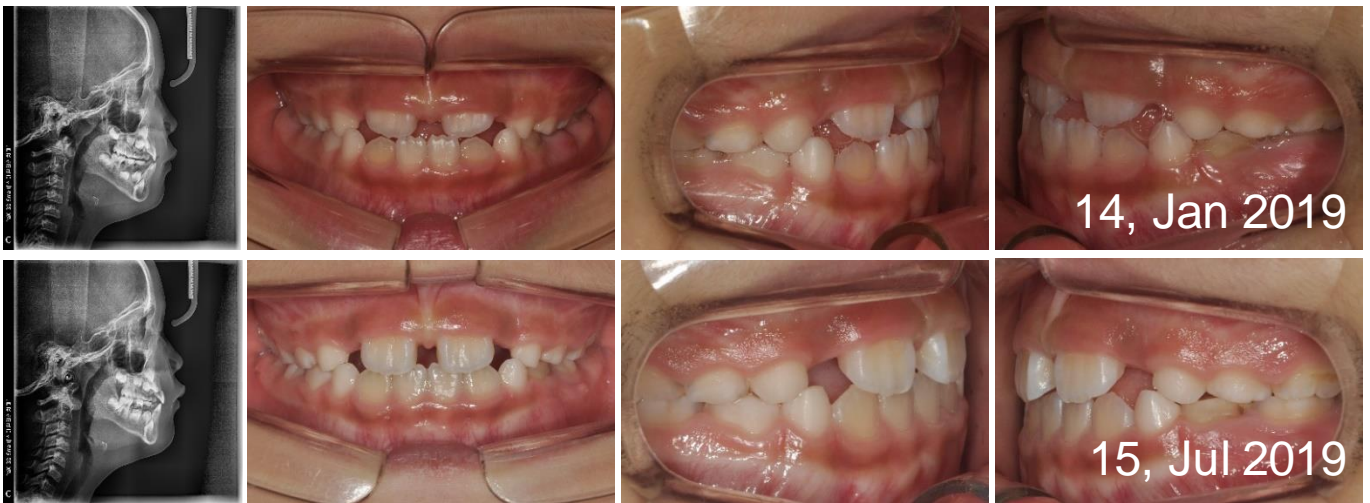This Patients was 5 years old girl and had a deciduous dentition. She had anterior crossbite and she had family history with Class III malocclusion. The Maxillary width was narrower than the mandible.

was worn for 9 months every 8 hours in the nighttime.

She was trained myofunctional therapy during treatment. anterior crossbite was improved but width problem is still existing. to resolve transverse problem, molar expansion will be needed soon.

She had functional shift from CO to CR. the PreOrtho<sup>®</sup> appliance

## Case #4

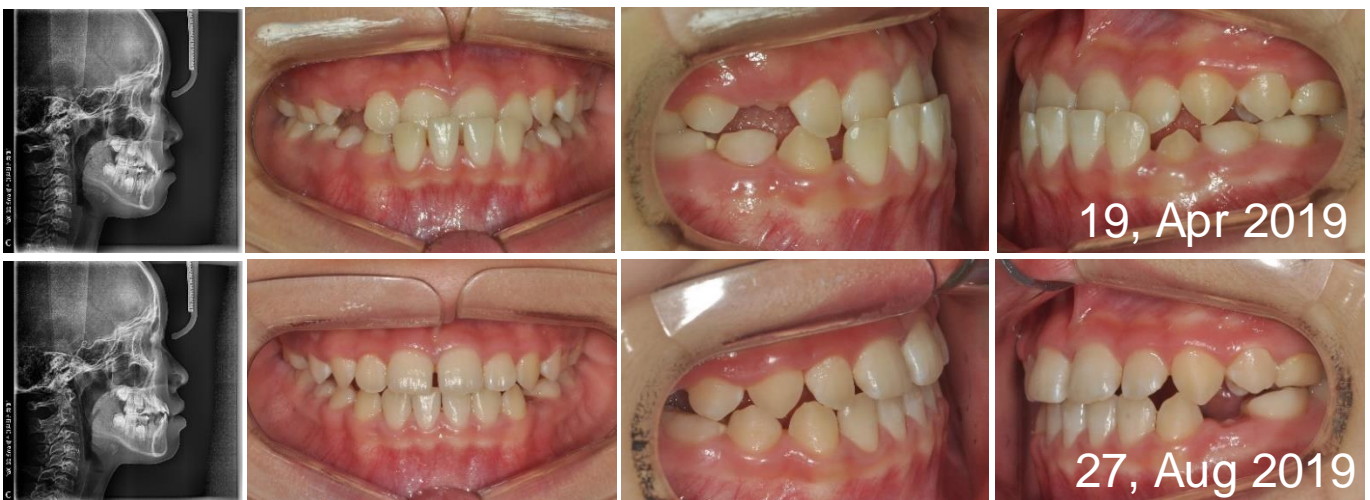

**Fig.6 Treatment result of case #4**

This patient was 6 years old boy with mixed dentition. Diastema was his chief complaint, but anterior crossbite was noted. To improve anterior crossbite, he wore PreOrtho<sup>®</sup> every night for 10 hours.

Next month, positive overjet was achieved. After 3 months, enameloplasty on a deciduous canine was done in order to remove canine interference. During the treatment, he was trained myofunctional exercise.

## Case #5



**Fig.7 Treatment result of case #5**

This patient was 10 years old girl with mixed dentition. Anterior crossbite is observed both in mother and sister who have straight profiles. Anterior premature contact was also noted.

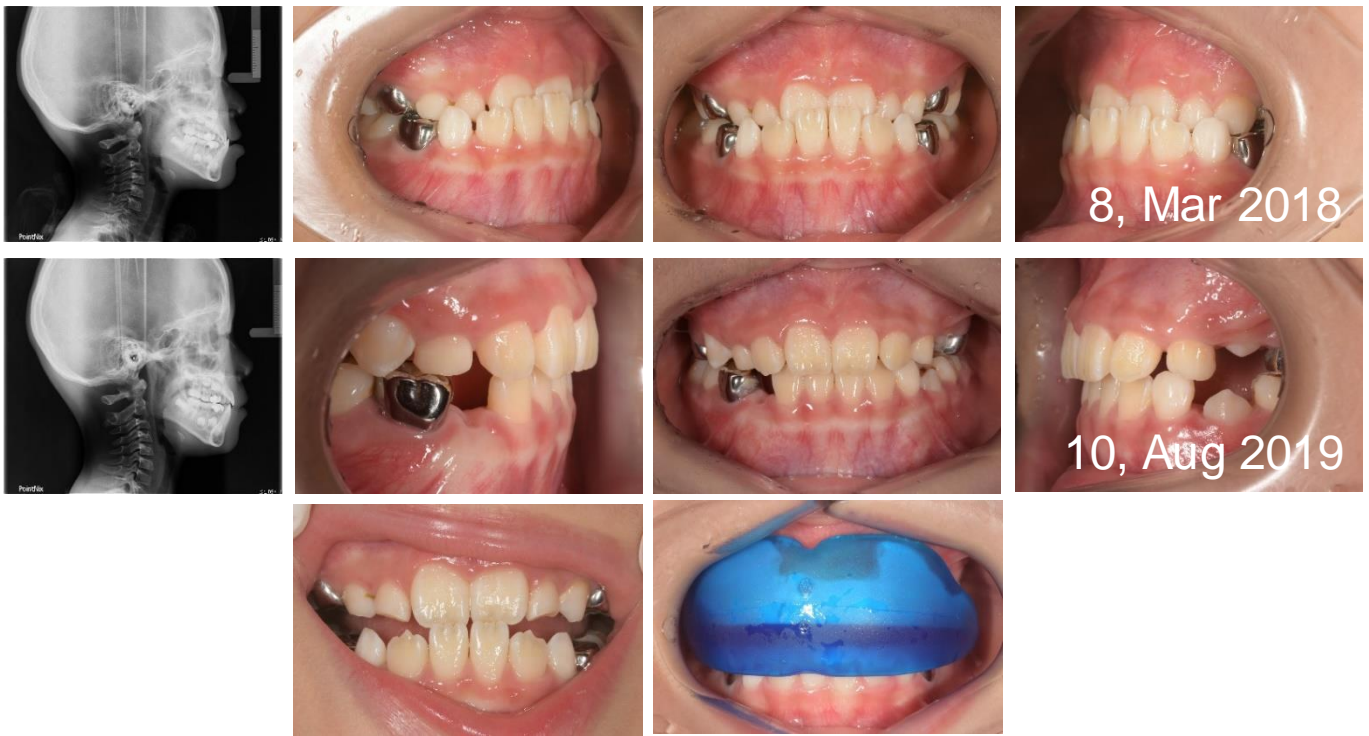
To improve anterior crossbite, she wore PreOrtho<sup>®</sup> every night

for 11 hours. Next month, incisor relationship changed to edge bite.

After 3 months, positive overjet was achieved. During the active treatment, she was trained myofunctional exercise.



## Case #6



**Fig.8 Treatment result of case #6**

This patient is 8 years old boy, He has anterior crossbite with CO-CR shifting, Diagnosed as functional Class III. PreOrtho<sup>®</sup> was recommended for his problems. He wears it for 15 months

with PreOrtho<sup>®</sup> until maxillary lateral incisors eruption. During the treatment, patient was educated for myofunction exercise and nasal breathing.

## Conclusions

Prefabricated functional appliance (PreOrtho<sup>®</sup>) with myofunctional therapy was effective for functional Class III patients with primary or early mixed dentition. It is made of soft material with adjustable with hot water and has little soft tissue irritation. Children can easily adapt to the appliance and showed good compliance. They wore it during the evening and night time about 6 to 10 hours.

The effect of this appliance is to induce the labial inclination of the maxillary anterior teeth, lingual inclination of the mandibular anterior teeth, increasing the width of maxilla and clockwise rotation of mandible.

To strengthen the muscles around the lips during the treatment, we taught them to train to close lip tightly and to raise up the tongue to swallow the saliva well. Also the importance of nasal breathing was emphasized to patient and parents.

The growth of the jaw is difficult to predict. It is also almost impossible to prevent overgrowth. However, it is the role of the orthodontist to remove the barriers to growth in a timely manner.

Therefore continuous and careful monitoring and following up the patient's growth will be the basis for good results.